

## ***IASOdopa® case report from the University Hospital Centre Zagreb, Croatia***

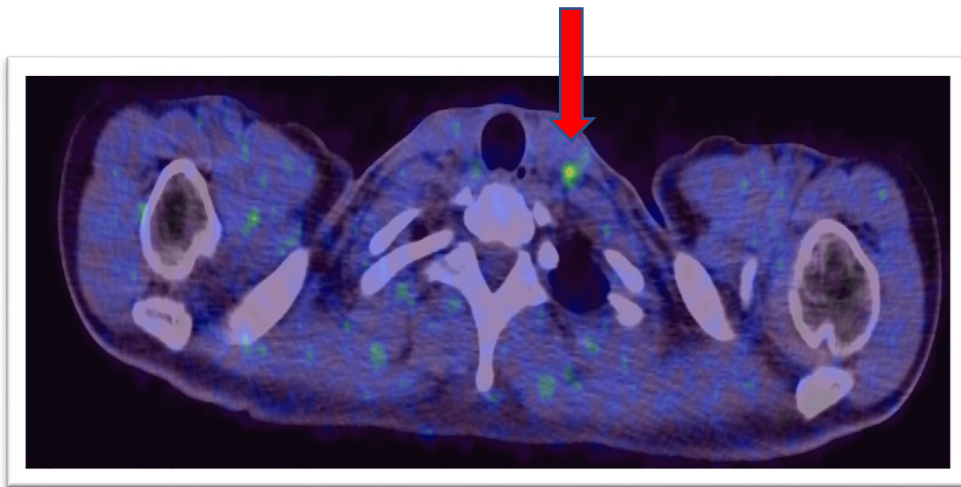
Thirty-year-old female patient after total thyroidectomy, due to the medullary thyroid carcinoma arrived for PET/CT scanning.

Her serum calcitonin level was 554.3 pmol/l.

<sup>18</sup>F-DOPA (IASOdopa®) PET scan showed increased tracer uptake in the lymph node at the base of the left neck (red arrow). Lymph node measured 0.6 cm and had not been visible on the CT.

Following the PET scan, the patient underwent a selective left neck dissection. Histological findings confirmed medullary thyroid carcinoma metastases in the lymph nodes of the left neck.

Postoperative serum calcitonin values dropped to 22.5 pmol/l.



Increased IASOdopa® uptake in the lymph nodes of the left neck histologically confirmed to be metastases from medullary thyroid carcinoma.

*This case report was kindly provided by **Prof. Dr. Drazen Huic and Dr. Anja Tea Golubic** from the Department of Nuclear Medicine and Radiation Protection, University Hospital Centre Zagreb, Croatia.*