

review article

^{18}F -fluorodeoxyglucose and ^{18}F -flumazenil positron emission tomography in patients with refractory epilepsy

Marina Hodolic^{1,2}, Raffi Topakian³, Robert Pichler⁴¹ Nuclear Medicine Research Department, Iason, Graz, Austria² Department of Nuclear Medicine, Palacký University Olomouc, Czech Republic³ Department of Neurology, Klinikum Wels-Grieskirchen, Wels, Austria⁴ Institute of Nuclear Medicine, Kepler Universitätsklinikum, Neuromed Campus, Linz, Austria

Radiol Oncol 2016;

Received 23 February 2016

Accepted 29 April 2016

Correspondence to: Marina Hodolič, M.D., Ph.D., Nuclear Medicine Research Department, Iason, Graz-Seiersberg, Feldkirchner Straße 4, Austria. Phone: +43 (0) 664 830 94 93; Fax: +43 316 284 300 14; E-mail: marina.hodolic@gmail.com

Disclosure: No potential conflicts of interest were disclosed.

Background. Epilepsy is a neurological disorder characterized by epileptic seizures as a result of excessive neuronal activity in the brain. Approximately 65 million people worldwide suffer from epilepsy; 20–40% of them are refractory to medication therapy. Early detection of disease is crucial in the management of patients with epilepsy. Correct localization of the ictal onset zone is associated with a better surgical outcome. The modern non-invasive techniques used for structural-functional localization of the seizure focus includes electroencephalography (EEG) monitoring, magnetic resonance imaging (MRI), single photon emission tomography/computed tomography (SPECT/CT) and positron emission tomography/computed tomography (PET/CT). PET/CT can predict surgical outcome in patients with refractory epilepsy. The aim of the article is to review the current role of routinely used tracer 2-deoxy-2- ^{18}F fluoro-D-glucose (^{18}F -FDG) as well as non routinely used ^{18}F -Flumazenil (^{18}F -FMZ) tracers PET/CT in patients with refractory epilepsy.

Conclusions. Functional information delivered by PET and the morphologic information delivered by CT or MRI are essential in presurgical evaluation of epilepsy. Nowadays ^{18}F -FDG PET/CT is a routinely performed imaging modality in localization of the ictal onset zone in patients with refractory epilepsy who are unresponsive to medication therapy. Unfortunately, ^{18}F -FDG is not an ideal PET tracer regarding the management of patients with epilepsy: areas of glucose hypometabolism do not correlate precisely with the proven degree of change within hippocampal sclerosis, as observed by histopathology or MRI. Benzodiazepine-receptor imaging is a promising alternative in nuclear medicine imaging of epileptogenic focus. The use of ^{11}C -FMZ in clinical practice has been limited by its short half-life and necessitating an on-site cyclotron for production. Therefore, ^{18}F -FMZ might be established as one of the tracers of choice for patients with refractory epilepsy because of better sensitivity and anatomical resolution.

Key words: epilepsy; nuclear medicine; PET/CT; ^{18}F -FDG; ^{18}F -Flumazenil

Introduction

Epilepsy is a neurological disorder characterized by epileptic seizures as a result of excessive neuronal activity in the brain (the word “epilepsy” is derived from the Greek word meaning to be attacked or seized). For diagnosis of epilepsy at least two unprovoked seizures are required. Metabolic, genetic

or structural conditions can be recognized as causes of epilepsy, but in 60% of patients, the cause remains unknown.¹ Approximately 65 million people worldwide suffer from epilepsy², 20–40% of them are refractory to medication therapy.³ Depending on the epilepsy syndrome, dietary changes, neurostimulation or surgery may be considered as treatment options in patients whose seizures do not

respond to medication therapy. With the advancement of surgical techniques and devices, surgical treatment has become the treatment of choice in patients who are unresponsive to medication therapy. In selected patients with focal structural lesions such as cortical dysplasia, mesial temporal sclerosis, vascular malformations and in some paediatric epilepsy syndromes, surgery may substantially reduce the frequency of epileptic seizures and improve the patient's quality of life. Several studies over the last decades support the statement that surgical treatment significantly improved long-term outcomes of seizure control.^{4,8}

Early detection of disease is crucial in the management of patients with epilepsy. Correct localization of the ictal onset zone is associated with a better surgical outcome. Epilepsy surgery may lead to seizure freedom. When "surgical cure" is impossible, epilepsy surgery may help achieve palliative goals such as minimizing the frequency and severity of seizures. Following successful epilepsy surgery, quality of life, cognition and behaviour may improve substantially.⁹ However, careful patient selection and weighing of risks and benefits are of paramount importance, as surgery may not only fail in terms of improving seizure control, but come with serious adverse events such as intracranial bleeding. Despite international guidelines recommending early and systematic assessment of patient's eligibility, epilepsy surgery is still being underused and referral of patients with drug refractory epilepsy is often delayed with deleterious consequences on outcome and quality of life.¹⁰

The scope of this paper on PET imaging in refractory epilepsy patients cannot cover all aspects of patient management including the range of indications, specific issues in children and adults, surgical techniques or predictors of outcome. For this, the interested reader is referred to a recent review of Ryvlin *et al.*¹¹

Different modalities in diagnosis of epilepsy

Non-invasive focus localisation of seizures precedes invasive intracranial electrodes procedures. The modern non-invasive techniques used for structural-functional localization of the seizure focus includes electroencephalography (EEG) monitoring, magnetic resonance imaging (MRI), single photon emission tomography/computed tomography (SPECT/CT) and positron emission tomography/computed tomography (PET/CT).

EEG has low sensitivity in the diagnosis of seizure disorders (25–56%).

MRI is a sensitive and specific imaging modality for identifying hippocampal sclerosis as well as other lesions responsible for epilepsy. However 1–1.5 T MRI still fails to reveal approximately 20% of abnormalities in patients with medically refractory epilepsy¹²; MRI may miss mild changes and subtle lesions. In patients with intractable extratemporal epilepsy, the most common underlying pathology is microscopic cortical dysplasia which sometimes cannot be detected by MRI and hence may pass unnoticed by ¹⁸F-FDG PET/CT as well. A recent study of 194 adult patients with medically refractory focal epilepsy showed that ¹⁸F-FDG PET/CT is helpful for decision making in 53% of presurgical patients with normal or discordant MRI.¹³ Advanced MRI technologies (MR spectroscopy, MR volumetry, MR perfusion) may provide additional and more precise information.

In recent years brain perfusion SPECT imaging has been widely used for detection of epileptic focus. In their meta-analysis, Devous *et al.* reported a 44% (interictal), 75% (postictal) and 97% (ictal) sensitivity of SPECT in patients with temporal lobe epilepsy.¹⁴ Extratemporal lobe epilepsy showed SPECT sensitivity in 66% (ictal) and in 40% (interictal) of patients.^{15,16}

PET procedures in patients with epilepsy

In recent years, multiple studies^{17–22} have demonstrated that ¹⁸F-FDG PET/CT can predict surgical outcome in patients with refractory epilepsy. Actually ¹⁸F-FDG PET/CT has proven to be the most sensitive imaging technique for presurgical localization of epileptogenic foci in patients with medically refractory partial epilepsy who have non-contributory MRI and EEG. In comparison to SPECT, PET technology provides much better resolution and allows quantitative measurement.^{23–26}

There is a variety of PET tracers used for imaging of epileptic focus: tracers that measure glucose metabolism, serotonin receptors and transport, oxygen metabolism, cerebral blood flow and other receptor binding.²⁷ PET scan findings at the area of a seizure focus are different according to the PET tracer used (Table 1). Multiple PET radiotracers for neurotransmitter and neuromodulator systems still form part of preclinical trials.

In this review article we focus on the routinely used tracer ¹⁸F-FDG as well as on ¹⁸F-labelled

flumazenil tracers which are less available but becoming popular.

^{18}F -FDG PET/CT in patients with epilepsy

The first application of ^{18}F -FDG PET/CT in patients with epilepsy dates back to the early 1980s.^{28,29} As glucose is the main energy source for the brain, a radioactive glucose analogue has been the most widely used tracer for PET imaging in patients with refractory epilepsy. There is a good match of glucose metabolism and neuronal activity. Glucose transporters (predominantly GLUT1) transfer ^{18}F -FDG from the blood into cells. Once in the cell, FDG is phosphorylated by hexokinase and forms FDG-6-phosphate. Further metabolism of FDG-6-phosphate is stopped and FDG-6-phosphate is essentially trapped in the cell.

In 2009 the European Association of Nuclear Medicine established an imaging protocol for ^{18}F -FDG PET/CT imaging of the brain.³⁰ According to this protocol patients should fast at least 4 hours before scanning. Psychotropic pharmaceuticals may influence regional metabolism of the glucose. Serum glucose levels must be checked before ^{18}F -FDG PET/CT examination. If the value is greater than 160 mg/dl, the patient must be rescheduled. Diabetic patients should undergo scanning in euglycemic state. At least 30 minutes before examination as well as 30 minutes after tracer injection patients must rest in a quiet dimly-lighted room. They should be instructed not to talk, read or to be otherwise active. ^{18}F -FDG dose for adults patients is 300–600 MBq in 2-D mode and 125–250 MBq in 3-D mode. For children, dose is calculated by body weight (EANM dosage card). Continuous EEG recording is required 2 hours before tracer injection (to exclude that tracer is not injected postictal state) and at least until 20 minutes after tracer injection. Static PET scan acquisition starts 30 up to 60 minutes after tracer injection and lasts for 15–30 minutes. There are small variations in the protocols depending on quality of imaging technology. In PET scans interpretation, combination of visual inspection and semiquantitative analysis is crucial. Semiquantitative analysis helps to detect abnormalities which are not present on visual inspection.

Physiological ^{18}F -FDG distribution is as follows: high in cerebral and cerebellar cortices and subcortical grey matter and mild in the white matter. In children and with normal aging there is decrease in

TABLE 1. Some PET tracers used for imaging of epileptic focus and PET scan findings

PET scan	Findings on PET scan
^{18}F -FDG <i>interictal</i>	Decreased metabolism
^{18}F -FDG <i>ictal</i>	Increased and decreased metabolism (complex pattern)
^{18}F -FDG <i>postictal</i>	Increased and decreased metabolism (complex pattern)
Serotonin receptor (e.g. ^{18}F -Mefway)	Reduced binding
Dopamine receptor (e.g. ^{18}F -Fallypride)	Reduced binding
^{18}F -Flumazenil (GABA receptor)	Decreased binding
^{15}O -H ₂ O <i>interictal</i>	Reduced perfusion
^{15}O -H ₂ O <i>ictal</i>	Increased perfusion

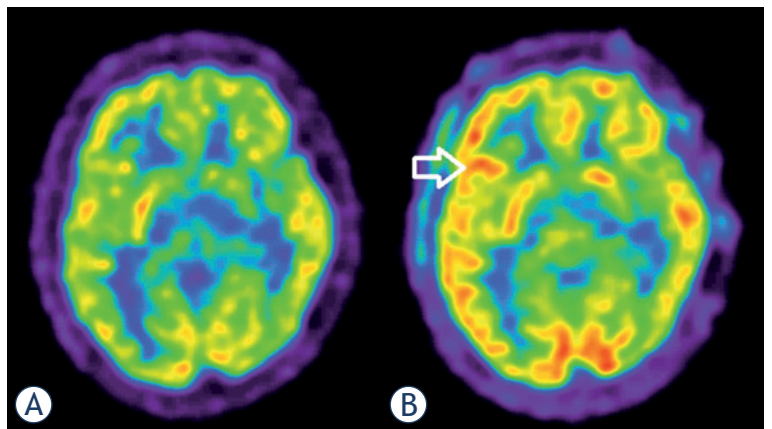


FIGURE 1. Focal epilepsy in 17 year old male patient. Interictal ^{18}F -FDG PET (A): physiological distribution of ^{18}F -FDG in the brain. Ictal ^{18}F -FDG PET (B): hypermetabolism frontolateral in the right hemisphere (arrow).

cerebral metabolic rates (particularly in lateral, medial frontal cortex and anterior cingulate cortex).^{31,32} Regions involving epileptic foci may present increased, reduced, or, absent metabolic activity.

^{18}F -FDG PET/CT scans in patients with epilepsy are usually obtained in the interictal phase. Ictal ^{18}F -FDG PET/CT appears to be highly sensitive (Figure 1), but is difficult to obtain because of unpredictability and very rapid onset of major seizures. In addition, medical personnel and the radiotracer must be available at the patient's bedside at the time of seizure onset. Postictal ^{18}F -FDG PET/CT scans can be very complex, and it represents a mishmash of increased and/or decreased metabolism, depending on the time of ^{18}F -FDG injection after the onset of seizure.

Interictal ^{18}F -FDG PET/CT in patients with epilepsy

The goal of implementing ^{18}F -FDG PET/CT in the management of patients with drug refractory epilepsy was to obtain functional imaging of interictal brain glucose metabolism. Multiple studies have shown that interictal ^{18}F -FDG PET/CT is more sensitive than interictal perfusion SPECT^{33-34,15}, because in the interictal period, reduction of regional glucose cerebral metabolism is more pronounced than reduction of cerebral perfusion.³⁵⁻³⁷

Neuronal loss due to chronic seizure activity, reduction in density of synapses, inhibitory processes in the interictal period and diaschisis also influence glucose hypometabolism, the characteristic sign of epilepsy on interictal ^{18}F -FDG PET/CT. Interictal ^{18}F -FDG PET/CT cannot precisely define the surgical margins, because some areas of hypometabolism extend beyond epileptic zones. Drzezga *et al.* showed that automated analysis of ^{18}F -FDG PET/CT scans in patients with epilepsy is more sensitive than visual analysis in patients with temporal lobe epilepsy and extra temporal lobe epilepsy.³⁶ The combination of MRI and interictal ^{18}F -FDG PET/CT will probably evolve as the future modality of choice to get the best results for presurgical evaluation.

Ictal ^{18}F -FDG PET/CT in patients with epilepsy

Ictal ^{18}F -FDG PET in the presurgical workup of refractory epilepsy is rarely performed; it is performed either in status epilepticus or in a status of induced epileptic seizures. As status epilepticus is defined as seizure longer than 30 minutes or more than one seizure within thirty minutes without the person returning to normal, ^{18}F -FDG PET is difficult to be obtained in those moments. Despite technical difficulties ictal ^{18}F -FDG PET has the advantage of a high spatial resolution. Ictal ^{18}F -FDG PET/CT shows hypermetabolism, although an ictal scan reveals a complex combination of hyper and hypometabolism and for that reason it is important to continuously monitor the patient with scalp EEG. A study from 2013 showed that in patients with incompatible EEG, MRI and clinical features, ictal ^{18}F -FDG PET/CT helped to localize the origin of status epilepticus.³⁸ Definition of an ictal onset zone is usually made visually with the support of semiquantitative analysis. A difference above 15% between the affected and the contralat-

eral side suggests significant physiological asymmetry.

Unfortunately, ^{18}F -FDG is not an ideal PET tracer regarding the management of patients with epilepsy. Areas of glucose hypometabolism do not correlate with the proven degree of change within hippocampal sclerosis, as observed by histopathology or MRI; the area of hypometabolism may be larger than the pathological seizure focus.³⁹ So, the presurgical definition of epileptogenic foci cannot be based on ^{18}F -FDG PET/CT imaging alone, because ^{18}F -FDG changes may appear larger than the real ictal onset zone. The reason for this anatomical-functional discrepancy has not been explained yet. However, ^{18}F -FDG PET/CT can reveal and confirm surgical targets and therefore represents a valuable tool in the management of patients with intractable epilepsy.

^{18}F - Flumazenil tracers for PET/CT of patients with epilepsy

Gamma-aminobutyric acid (GABA) is the most important inhibitory neurotransmitter in the central nervous system.⁴⁰⁻⁴³ Its main role consists of reducing neuronal excitability and regulating muscle tone. There are two types of GABA receptors: GABA_A and GABA_B; benzodiazepine receptors are modulatory sites on GABA_A receptors. Benzodiazepine distribution in the human brain includes the occipital cortex, temporal cortex, cerebellum, thalamus, and the pons. The majority of GABA_A receptors are benzodiazepine-sensitive, but there are also GABA_A receptors which are insensitive to classical benzodiazepines. Benzodiazepines enhance the action of GABA on its receptors, thus having anticonvulsant, sedative, hypnotic, anxiolytic and muscle-relaxant effects.

Flumazenil blocks the benzodiazepine sites on GABA_A receptors and thus antagonizes the action benzodiazepines have on the central nervous system. Flumazenil was introduced in 1987 and over time it was used as an antidote for the treatment of benzodiazepine overdoses. In epileptogenic regions a reduced level of benzodiazepine receptors is found⁴⁴; also, irreversible ischemic cortical damage after stroke⁴⁵, Alzheimer disease^{46,47} chronic alcoholism⁴⁸ and schizophrenia⁴⁹ may influence benzodiazepine complex density.

In the 1980s, Flumazenil was proposed as a promising new marker for imaging of benzodiazepine receptors by PET. The substance was ini-

tially labelled with Carbon-11 (^{11}C -FMZ)⁵⁰ and used in some studies: the majority of patients with seizures refractory to medical treatment had hippocampal sclerosis characterized by neuronal loss and gliosis, which was detected by this positron-labelled GABA_A receptor antagonist.⁵¹ Six years later a SPECT agent, ^{123}I -iomazenil, was synthesized.^{52,53} Both compounds showed high benzodiazepine binding potential in the brain. However, use of ^{11}C -FMZ in clinical practice has been limited by its short half-life, necessitating an on-site cyclotron for production, and multiple syntheses if several subjects have to be examined. The first paper on a fluorinated analogue of flumazenil was published in 1992.⁵⁴ ^{18}F -labelled PET radiotracers are more suited for clinical use. Also, the shorter positron range of ^{18}F provides better image resolution, which may enhance the detection of small pathological complexes such as epileptic foci. Following this, several ^{18}F -labelled FMZ tracers, including 5-(2'-[^{18}F]fluoroethyl) flumazenil (^{18}F -FEFMZ), 3-(2'-[^{18}F]fluoroflumazenil (^{18}F -FFMZ), 5-(2'-[^{18}F]fluoroethyl)flumazenil (^{18}F -FEF) and [^{18}F]flumazenil (^{18}F -FMZ) have been developed.⁵⁵⁻⁶⁰ Compared to ^{11}C -FMZ, ^{18}F -FEFMZ has lower receptor affinity, and higher nonspecific binding due to faster metabolism and faster kinetics. ^{18}F -FFMZ also has faster kinetics than ^{11}C -FMZ. Compared to ^{11}C -FMZ, ^{18}F -FEF has lower affinity to benzodiazepine receptors, rapid kinetics in the brain and faster metabolism.⁵⁵⁻⁶⁰ ^{18}F -FMZ, with an identical structure to ^{11}C -FMZ, has been shown to have similar pharmacokinetics and peripheral metabolism and PET imaging characteristics as ^{11}C -FMZ.

^{18}F -FMZ has been established as the tracer of choice for patients with refractory epilepsy in some neurological centres in Europe. PET/CT imaging using flumazenil tracers identify a more restricted region of abnormality in the epileptogenic zone than ^{18}F -FDG PET/CT.⁶¹ In comparison to ^{18}F -FDG PET/CT scans benzodiazepine-receptor scans appears "sharper" (Figure 2, 3).

Imaging protocol for PET/CT with ^{18}F -labelled flumazenil radiotracers is almost similar to protocol for ^{18}F -FDG PET/CT, except no serum glucose level measurement is required. All flumazenil tracers bind non-selectively to all benzodiazepine receptor subtypes, so pre-treatment with unlabelled flumazenil can result in reduced tracer uptake on benzodiazepine receptors. As a young modality, benzodiazepine-receptor PET imaging is still strengthening its place in neurology.

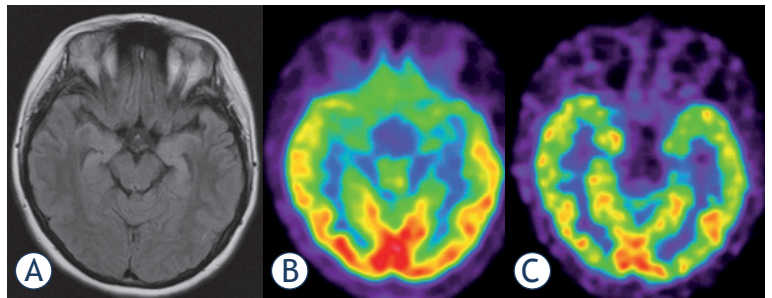


FIGURE 2. ^{18}F -FDG PET (B) scan vs. ^{18}F -Flumazenil PET (C) in a 19 year old female patient with bilateral hippocampal sclerosis as shown by MRI (A). Both PET modalities present low temporomesial uptake being larger on the left side, but benzodiazepine-receptor imaging appears sharper and presents a focal defect.

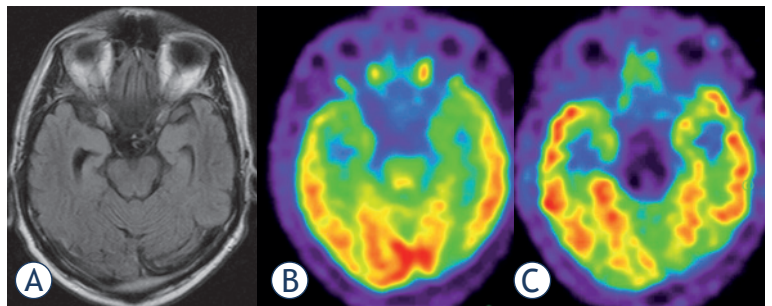


FIGURE 3. Focal epilepsy in 56 year old male patient. (A) MRI: astrogliosis of the right hippocampus (later proven by histology); (B) ^{18}F -FDG PET: minimal temporomesial hypometabolism of both sides; (C) ^{18}F -Flumazenil PET: focal defect of tracer uptake at the right hippocampus.

Conclusions

Functional information delivered by PET and the morphologic information delivered by CT or MR are essential in presurgical evaluation of epilepsy. Nowadays ^{18}F -FDG PET/CT is a routinely performed imaging modality in localization of the ictal onset zone in patients with refractory epilepsy who are unresponsive to medication therapy. Unfortunately, ^{18}F -FDG is not an ideal PET tracer regarding the management of patients with epilepsy: areas of glucose hypometabolism do not correlate precisely with the proven degree of change within hippocampal sclerosis, as observed by histopathology or MRI. Benzodiazepine-receptor imaging is a promising alternative in nuclear medicine imaging of epileptogenic focus. The use of ^{11}C -FMZ in clinical practice has been limited by its short half-life and necessitating an on-site cyclotron for production. Therefore, ^{18}F -FMZ might be established as one of the tracers of choice for patients with refrac-

tory epilepsy because of better sensitivity and anatomical resolution.

Multiple new PET tracers for presurgical evaluation of patients with epilepsy are still under pre-clinical investigations; tracers for neurotransmitter and neuromodulator systems, including the GABA, serotonin, dopamine, glutamate, acetylcholine, adenosine and opioid systems.

References

- National Institute for Health and Clinical Excellence. Chapter 1. Introduction. In: National Clinical Guideline Centre, editors. *The epilepsies: the diagnosis and management of the epilepsies in adults and children in primary and secondary care*. London: Royal College of Physicians (UK); 2012. p. 21-8.
- Thurman DJ, Beghi E, Begley CE, Berg AT, Buchhalter JR, Ding D, et al. ILAE commission on epidemiology. Standards for epidemiologic studies and surveillance of epilepsy. *Epilepsia* 2011; **52**(Suppl 7): 2-26.
- Kwan P, Brodie MJ. Early identification of refractory epilepsy. *N Engl J Med* 2000; **342**: 314-9.
- Kelly KM, Chung SS. Surgical treatment for refractory epilepsy: review of patient evaluation and surgical options. *Epilepsy Res Treat* 2011; **2011**: 303624.
- Chou CC, Shih YH, Yen DJ, Kwan SY, Yu HY. Long-term health-related quality of life in drug-resistant temporal lobe epilepsy after anterior temporal lobectomy. *Epileptic Disord* 2015; **17**: 177-83.
- Gomez-Alonso J, Bellas-Lamas P. Surgical treatment for drug-resistant epilepsy. *JAMA* 2015; **313**:1572.
- Liu SY, Yang XL, Chen B, Hou Z, An N, Yang MH, et al. Clinical outcomes and quality of life following surgical treatment for refractory epilepsy: a systematic review and meta-analysis. *Medicine (Baltimore)* 2015; **94**: e500.
- Wiebe S, Blume WT, Girvin JP, Eliasziw M. A randomised, controlled trial of surgery for temporal lobe epilepsy. *N Engl J Med* 2001; **345**: 365-7.
- Taft C, Sager Magnusson E, Ekstedt G, Malmgren K. Health-related quality of life, mood, and patient satisfaction after epilepsy surgery in Sweden-a prospective controlled observational study. *Epilepsia* 2014; **55**: 878-85.
- Engel J Jr, Wiebe S, French J, Sperling M, Williamson P, Spencer D, et al. Practice parameter: temporal lobe and localized neocortical resections for epilepsy: report of the Quality Standards Subcommittee of the American Academy of Neurology, in association with the American Epilepsy Society and the American Association of Neurological Surgeons. *Neurology* 2003; **60**: 538-47.
- Ryvlin P, Cross JH, Rheims S. Epilepsy surgery in children and adults. *Lancet Neurol* 2014; **13**: 1114-26.
- Lehericy S, Semah F, Hasboun D, Dormont D, Clemenceau S, Granat O, et al. Temporal lobe epilepsy with varying severity: MRI study of 222 patients. *Neuroradiology* 1997; **39**: 788-96.
- Rathore C, Dickson JC, Teotônio R, Ell P, Duncan JS. The utility of ¹⁸F fluorodeoxyglucose PET (FDG PET) in epilepsy surgery. *Epilepsy Res* 2014; **108**: 1306-14.
- Devous M, Thisted R, Morgan G, Leroy R, Rowe C. SPECT brain imaging in epilepsy: a meta-analysis. *J Nucl Med* 1998; **39**: 285-93.
- Spencer S. The relative contributions of MRI, SPECT and PET imaging in epilepsy. *Epilepsia* 1994; **35**: 572-89.
- Weil S, Noachtar S, Arnold S, Yousry TA, Winkler PA, Tatsch K. Ictal ECD-SPECT differentiate between temporal and extratemporal epilepsy: confirmation by excellent postoperative seizure control. *Nucl Med Commun* 2001; **22**: 233-7.
- Blum DE, Ehsan T, Dungan D, Karis JP, Fisher RS. Bilateral temporal hypometabolism in epilepsy. *Epilepsia* 1998; **39**: 651-9.
- Willmann O, Wennberg R, May T, Woermann FG, Pohlmann-Eden B. The contribution of ¹⁸F-FDG PET in preoperative epilepsy surgery evaluation for patients with temporal lobe epilepsy. A meta-analysis. *Seizure* 2007; **16**: 509-20.
- Taft C, Sager Magnusson E, Ekstedt G, Malmgren K. Health-related quality of life, mood, and patient satisfaction after epilepsy surgery in Sweden-a prospective controlled observational study. *Epilepsia* 2014; **55**: 878-85.
- Swartz BE, Tomiyasu U, Delgado-Escueta AV, Mandelkern M, Khonsari A. Neuroimaging in temporal lobe epilepsy: test sensitivity and relationships to pathology and post-surgical outcome. *Epilepsia* 1992; **33**: 624-34.
- Manno EM, Sperling MR, Ding X, Jaggi J, Alavi A, O'Connor MJ, et al. Predictors of outcome after anterior temporal lobectomy: Positron emission tomography. *Neurology* 1994; **44**: 2331-6.
- Theodore WH, Sato S, Kufta C, Balish MB, Bromfield EB, Leiderman DB. Temporal lobectomy for uncontrolled seizures: The role of positron emission tomography. *Ann Neurol* 1992; **32**: 789-94.
- Rathore C, Dickson JC, Teotônio R, Ell P, Duncan JS. The utility of ¹⁸F-fluorodeoxyglucose PET (FDG PET) in epilepsy surgery. *Epilepsy Res* 2014; **108**: 1306-14.
- Singhal T, Alavi A, Kim CK. Brain: positron emission tomography tracers beyond [¹⁸F]fluorodeoxyglucose. *PET Clin* 2014; **9**: 267-76.
- Inaji M, Maehara T. PET, SPECT, and MEG in the diagnosis of epilepsy. *Nihon Rinsho* 2014; **72**: 827-33.
- Casse R, Rowe CC, Newton M, Berlangieri SU, Scott AM. Positron emission tomography and epilepsy. *Mol Imaging Biol* 2002; **4**: 338-51.
- Ismet Sarikaya. PET studies in epilepsy. *Am J Nucl Med Mol Imaging* 2015; **5**: 416-30.
- Kuhl E, Engel J, Phelps E, Selin C. Epileptic patterns of local cerebral metabolism and perfusion in humans determined by emission computed tomography of ¹⁸FDG and ¹⁵NH₃. *Ann Neurol* 1980; **18**: 348-60.
- Engel J, Kuhl E, Phelps E, Crandall H. Comparative localization of epileptic foci in partial epilepsy by PCT and EEG. *Ann Neurol* 1983; **12**: 529-37.
- Varrone A, Asenbaum S, Vander Borgh T, Booi J, Nobili F, Nägren K, et al. EANM procedure guidelines for PET brain imaging using [¹⁸F]FDG, version 2. *Eur J Nucl Med Mol Imaging* 2009; **36**: 2103-10.
- Herholz K, Salmon E, Perani D, Baron JC, Holthoff V, Frölich L, et al. Discrimination between Alzheimer dementia and controls by automated analysis of multicenter FDG PET. *Neuroimage* 2002; **17**: 302-16.
- Loessner A, Alavi A, Lewandrowski KU, Mozley D, Souder E, Gur RE. Regional cerebral function determined by FDG-PET in healthy volunteers: normal patterns and changes with age. *J Nucl Med* 1995; **36**: 1141-9.
- Won HJ, Chang KH, Cheon JE, Kim HD, Lee DS, Han MH, et al. Comparison of MR imaging with PET and ictal SPECT in 118 patients with intractable epilepsy. *AJNR Am J Neuroradiol* 1999; **20**: 593-9.
- Hwang SI, Kim JH, Park SW, Han MH, Yu IK, Lee SH, et al. Comparative analysis of MR imaging, positron emission tomography, and ictal single-photon emission CT in patients with neocortical epilepsy. *Am J Neuroradiol* 2001; **22**: 937-46.
- Fink GR, Pawlik G, Stefan H, Pietrzyk U, Wienhard K, Heiss WD. Temporal lobe epilepsy: evidence for interictal uncoupling of blood flow and glucose metabolism in temporomesial structures. *J Neurol Sci* 1996; **137**: 28-34.
- Zubal IG, Avery RA, Stokking R, Studholme C, Corsi M, Dey H, et al. Ratio-images calculated from interictal positron emission tomography and single-photon emission computed tomography for quantification of the uncoupling of brain metabolism and perfusion in epilepsy. *Epilepsia* 2000; **41**:1560-6.
- Buch K, Blumenfeld H, Spencer S, Novotny E, Zubal IG. Evaluating the accuracy of perfusion/metabolism (SPET/PET) ratio in seizure localization. *Eur J Nucl Med Mol Imaging* 2008; **35**: 579-88.
- Desai A, Bekelis K, Thadani VM, Roberts DW, Jobst BC, Duhaime AC, et al. Interictal PET and ictal subtraction SPECT: sensitivity in the detection of seizure foci in patients with medically intractable epilepsy. *Epilepsia* 2013; **54**: 341-50.

39. Drzezga A, Arnold S, Minoshima S, Noachtar S, Szecsi J, Winkler P, et al. ¹⁸F-FDG PET studies in patients with extratemporal and temporal epilepsy: evaluation of an observer-independent analysis. *J Nucl Med* 1999; **40**: 737-46.
40. Javeria N, Rajesh I, Seetharam R. Ictal PET in presurgical workup of refractory extratemporal epilepsy. *Ann Indian Acad Neurol* 2013; **16**: 676-7.
41. Siclari F, Prior JO, Rossetti AO. Ictal cerebral positron emission tomography (PET) in focal status epilepticus. *Epilepsy Res* 2013; **105**: 356-61.
42. Engel J Jr, Brown WJ, Kuhl DE, Phelps ME, Mazziotta JC, Crandall PH. Pathological findings underlying focal temporal lobe hypometabolism in partial epilepsy. *Ann Neurol* 1982; **12**: 518-28.
43. Watanabe M, Maemura K, Kanbara K, Tamayama T, Hayasaki H. GABA and GABA receptors in the central nervous system and other organs. *Int Rev Cytol* 2002; **213**: 1-47.
44. Sieghart W. Pharmacology of benzodiazepine receptors: an update. *J Psychiatry Neurosci* 1994; **19**: 24-9.
45. Derry JM, Dunn SM, Davies M. Identification of a residue in the gamma-aminobutyric acid type A receptor alpha subunit that differentially affects diazepam-sensitive and -insensitive benzodiazepine site binding. *J Neurochem* 2004; **88**: 1431-8.
46. Goldfrank, Lewis R. Goldfrank's toxicologic emergencies. New York: McGraw-Hill; 2002.
47. Savic I, Persson A, Roland P, Pauli S, Sedvall G, Widén L. In-vivo demonstration of reduced benzodiazepine receptor binding in human epileptic foci. *Lancet* 1988; **2**: 863-6.
48. Heiss WD, Kracht L, Grond M, Rudolf J, Bauer B, Wienhard K, et al. [¹¹C]Flumazenil/H(2)O positron emission tomography predicts irreversible ischemic cortical damage in stroke patients receiving acute thrombolytic therapy. *Stroke* 2000; **31**: 366-9.
49. Mayer M, Koeppe RA, Frey KA, Foster NL, Kuhl DE. Positron emission tomography measures of benzodiazepine binding in Alzheimer's disease. *Arch Neuro* 1995; **52**: 314-7.
50. Pascual B, Prieto E, Arbizu J, Marti-Climent JM, Peñuelas I, Quincoces G, et al. Decreased carbon-11-flumazenil binding in early Alzheimer's disease. *Brain* 2012; **135**: 2817-25.
51. Litton JE, Neiman J, Pauli S, Farde L, Hindmarsh T, Halldin C, et al. PET analysis of [¹¹C]flumazenil binding to benzodiazepine receptors in chronic alcohol-dependent men and healthy controls. *Psychiatry Res* 1993; **50**: 1-13.
52. Benes FM, Vincent SL, Alsterberg G, Bird ED, SanGiovanni JP. Increased GABAA receptor binding in superficial layers of cingulate cortex in schizophrenics. *J Neurosci* 1992; **12**: 924-9.
53. Maziere M, Hantraye P, Prenant C, Sastre J, Comar D. Synthesis of ethyl 8-fluoro-5,6-dihydro-5-[¹¹C]methyl-6-oxo-4H-imidazo [1,5-a] [1,4]benzodiazepine-3-carboxylate (RO 15.1788-11C): a specific radioligand for the in vivo study of central benzodiazepine receptors by positron emission tomography. *Int J Appl Radiat Isot* 1984; **35**: 973-6.
54. Savic I, Ingvar M, Stone-Elander S. Comparison of [¹¹C]flumazenil and [¹⁸F]FDG as PET markers of epileptic foci. *J Neural Neurosurg Psychiatry* 1993; **56**: 615-21.
55. Boundy KL, Rowe CC, Black AB, Kitchener MI, Barnden LR, Sebben R, et al. Localization of temporal lobe epileptic foci with iodine-123 iododexetimide cholinergic neuroreceptor single-photon emission computed tomography. *Neurology* 1996; **47**: 1015-20.
56. Beer HF, Bläuenstein PA, Hasler PH, Delaloye B, Riccabona G, Bangerl I, et al. In vitro and in vivo evaluation of iodine-123-Ro 16-0154: a new imaging agent for SPECT investigations of benzodiazepine receptors. *J Nucl Med* 1990; **31**: 1007-14.
57. Samson Y, Hantraye P, Baron JC, Soussaline F, Comar D, Mazière M. Kinetics and displacement of [¹¹C]RO 15-1788, a benzodiazepine antagonist, studied in human brain in vivo by positron tomography. *Eur J Pharmacol* 1985; **110**: 247-51.
58. Moerlein SM, Perlmutter JS. Binding of 5-(2'-[¹⁸F]fluoroethyl)flumazenil to central benzodiazepine receptors measured in living baboon by positron emission tomography. *Eur J Pharmacol* 1992; **218**: 109-15.
59. Leveque P, Labar D, Gallez B. Biodistribution, binding specificity and metabolism of [¹⁸F]fluoroethylflumazenil in rodents. *Nucl Med Biol* 2001; **28**: 809-14.
60. Grunder G, Siessmeier T, Lange-Asschenfeldt C, Vernaleken I, Buchholz HG, Stoeter P, et al. [¹⁸F]Fluoroethylflumazenil: a novel tracer for PET imaging of human benzodiazepine receptors. *Eur J Nucl Med* 2001; **28**: 1463-70.
61. Mitterhauser M, Wadsak W, Wabnegger L, Mien L-K, Togel S, Langer O, et al. Biological evaluation of 2'-[¹⁸F]fluoroethylflumazenil ([¹⁸F]FFMZ), a potential GABA receptor ligand for PET. *Nucl Med Biol* 2004; **31**: 291-5.
62. Chang YS, Jeong JM, Yoon YH, Kang WJ, Lee SJ, Lee DS, et al. Biological properties of 2'-[¹⁸F]fluoroethylflumazenil for central benzodiazepine receptor imaging. *Nucl Med Biol* 2005; **32**: 263-8.
63. Ryzhikov NN, SenecaN, Krasikova RN, GomzinaNA, Shchukin E, Fedorova OS, et al. Preparation of highly specific radioactivity [¹⁸F] flumazenil and its evaluation in cynomolgus monkey by positron emission tomography. *Nucl Med Biol* 2005; **32**: 109-16.
64. Vivash L, Gregoire MC, Lau EW, Ware RE, Binns D, Roselt P, et al. ¹⁸F-flumazenil: a γ-aminobutyric acid A-specific PET radiotracer for the localization of drug-resistant temporal lobe epilepsy. *J Nucl Med* 2013; **54**: 1270-7.